
Guideline

Consensus on the management of pediatric deep partial-thickness burn wounds (2023 edition)

Yan Liu* and Chinese Burn Association

Department of Burn, Ruijin Hospital, Shanghai Jiao Tong University School of Medicine, Shanghai 200025, China

*Correspondence. Email: rjliuyan@126.com

Received 9 August 2023; Revised 21 October 2023; Accepted 21 October 2023

Abstract

Burns are a main cause of accidental injuries among children in China. Because of the unique wound repair capacity and demand for growth in pediatric patients, the management of pediatric deep partial-thickness burn wounds involves a broader range of treatment options and controversy. We assembled experts from relevant fields in China to reach a consensus on the key points of thermal-induced pediatric deep partial-thickness burn-wound management, including definition and diagnosis, surgical treatments, nonsurgical treatment, choice of wound dressings, growth factor applications, infectious wound treatment, scar prevention and treatment. The committee members hope that the Expert Consensus will provide help and guiding recommendations for the treatment of pediatric deep partial-thickness burn wounds.

Key words: Deep partial thickness burns, Pediatric, Wound management, Expert consensus

Background

Burns are the main cause of accidental injuries among children in China. Due to the unique physiological structure of the skin and the specific pathological characteristics of burns, burn wounds in pediatric patients tend to progress into full-thickness wounds and are often accompanied by the formation of hypertrophic scars. These problems usually result in long-term psychological and physiological impacts on patients and their families. Deep partial-thickness burn wounds have the potential to spontaneously heal. Compared to other deep burns, a broader range of treatment options is available for deep partial-thickness burn wounds; however, the management of pediatric deep partial-thickness burn wounds remains controversial. Since there is no current consensus worldwide on the management of pediatric deep partial-thickness burn wounds [1,2], we assembled experts from relevant fields in China to develop a national consensus on the management of pediatric deep partial-thickness burn

wounds caused by thermal injury and provide guidelines and recommendations for the treatment of such wounds.

Methods

Consensus development process

The Consensus was developed based on the conventional treatments and clinical experience of burn physicians in China. It also references relevant domestic and international publications and follows the approach of evidence-based medicine. An expert group on the Consensus consisted of experts in burn surgery, pediatrics, anesthesiology, and evidence-based medicine, including a foreign expert in pediatric burn surgery (see the name list of experts in the Reference section). The expert group oversaw discussions and made suggestions. There were working groups focused on literature publication search, evidence grading, and consensus writing. Working groups collaborated with expert groups

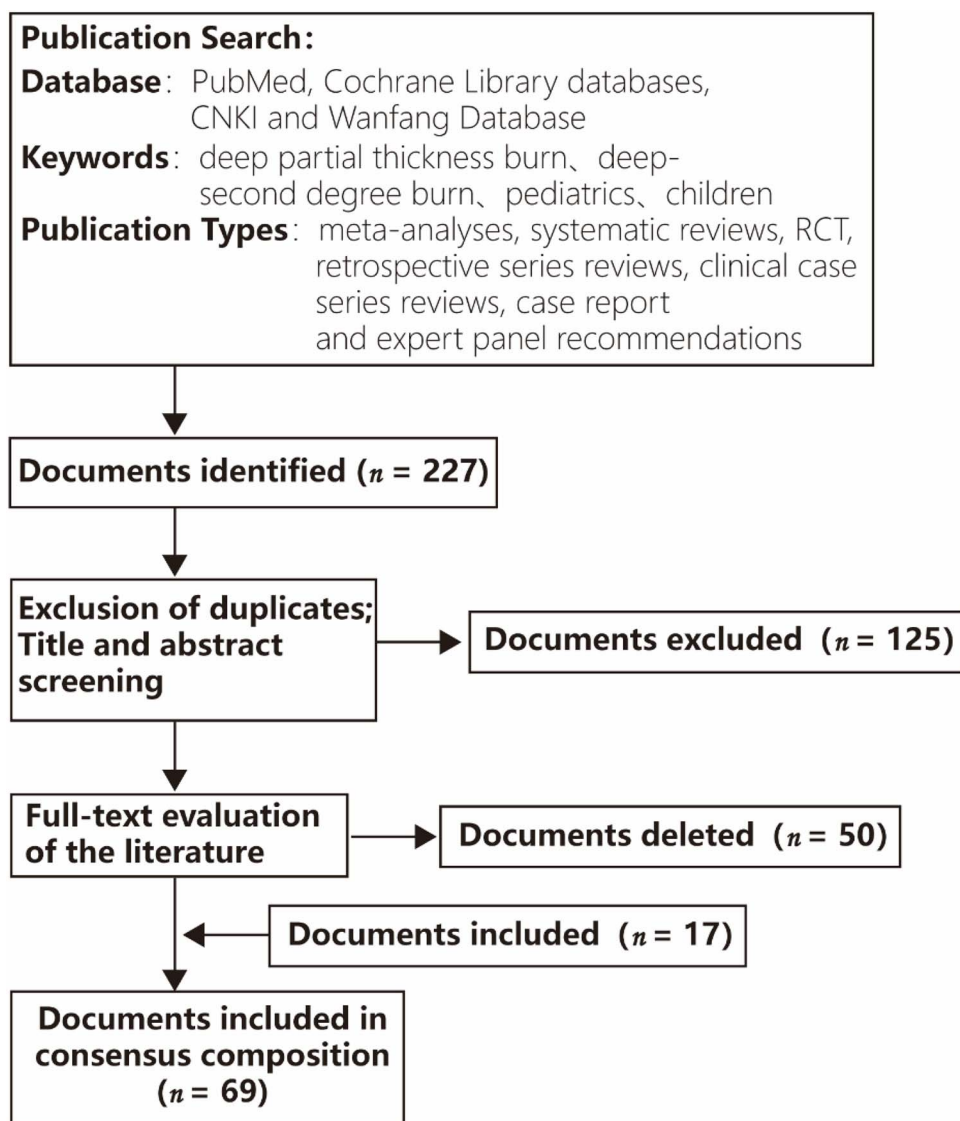


Figure 1. Publications searching process

during the development process from initializing to finalizing the consensus.

Publication search

The publication search working group searched publications on the diagnosis and treatment of pediatric deep partial-thickness burns using the strategy outlined below. The keywords used were ‘deep partial-thickness burn,’ ‘deep second-degree burn,’ ‘pediatrics’ and ‘children.’ We searched the following databases: PubMed, the Cochrane Library databases, China National Knowledge Infrastructure (CNKI), and Wanfang Database. The publication date spanned from the establishment of the databases to June 1, 2020. We limited our search to human diseases and the following publication types: meta-analyses, systematic reviews, randomized controlled trials (RCTs), retrospective series reviews, clinical case series reviews, case reports, and expert panel recommendations. We searched a total

of 227 subject-related documents and reviewed the titles and abstracts of individual documents to perform an initial literature screening. A subsequent 102 documents were screened, and their full texts were thoroughly reviewed and evaluated. Among these, 52 documents met the inclusion criteria (Figure 1) and were ultimately included in the initial version of the Consensus. An additional 11 documents were included during the process of achieving consensus, resulting in a total of 63 documents being selected for the study.

Consensus writing, recommendation level, and evidence grading

The development of consensus is briefly explained below. A consensus writing group reviewed the selected literature and proposed the first draft and the initial set of clinical issues that were further reviewed, discussed and agreed upon by the expert group. The initial set consisting of 13 questions related to the treatment of pediatric deep partial-thickness

Table 1. 2001 edition of the grading criteria from the Oxford Center for Evidence-based Medicine

Evidence grade	Definition
Ia	Systematic reviews of homogeneous RCTs
Ib	Single RCT (with narrow confidence interval)
Ic	Full or no case series
IIa	Systematic reviews of homogeneous cohort studies
IIb	Single cohort studies (including low-quality RCT, e.g. follow-up rate < 80%)
IIc	Outcome studies, ecological studies
IIIa	Systematic reviews of homogeneous case-control studies
IIIb	Single case control
IV	Case series studies (including low-quality cohort and case-control studies)
V	Expert opinions based on experience without rigorous argument

burns was surveyed online. The survey scored these clinical issues on a scale of 1 ('extremely unimportant') to 5 ('extremely important'). A total of 449 questionnaires were submitted by medical doctors. All clinical issues were given an importance score of more than 4 points. Furthermore, the writing group collected and summarized 6 additional clinical issues based on the open-ended questions of clinical interest in the questionnaire. The writing group made 18 consensus recommendations for the treatment based on the 19 clinical issues and submitted them to the expert group for a first round of review.

In the first round of review, two options were available for the experts to respond: agree or disagree. Each respondent was required to make a single choice and provide necessary textual descriptions for further revision. The first round involved a total of 83 experts, who evaluated 18 recommended consensus items in the first draft. After gathering feedback from the first round, the writing group statistically analyzed the responses and assigned a recommendation level according to the analysis results. The recommendation level for the consensus items was defined as follows: a 'Highly recommended' was given if a recommended item was agreed upon by more than 90% of the experts; a 'Recommended' was given if it was agreed upon by 70% to 90% of them; and the item was not included in the consensus recommendation if the percentage of the experts that agreed on it was below 70%. Upon discussion, the writing group adopted details of the recommendation and other essential content to a revised draft based on the comments and feedback received during the first round of review.

The revised draft was submitted to the expert group for a second round of review by using the same evaluation method as the first round. A total of 67 experts were involved in the second round of review. The final version contained 18 recommended consensus items in total. Every consensus item was composed of a recommendation, recommendation level, and evidence grades.

The consensus recommendation was calibrated with the 2001 edition of the grading criteria from the Oxford Center for Evidence-Based Medicine as shown in Table 1. The evidence grading group members independently assessed

each piece of evidence and determined the evidence grading after two repeated assessments.

After two rounds of conference discussions and two rounds of questionnaire discussions using the Delphi method, the final recommendations were finalized and named the *National Expert Consensus on Diagnosis and Treatment of Pediatric Deep Partial-Thickness Burn Wounds (2023 Edition)*. The Consensus aims to establish a standardized treatment plan based on evidence-based medical research and expert consensus, and the treatment plan will serve as an applied reference for clinicians.

Definition of pediatric deep partial-thickness burn wounds

For this study, children's ages were categorized into newborn (from birth to 28 days), infancy (under 1 year old), early childhood (from 1 to 3 years old), preschool (from 3 years old to 6 or 7 years old before going to school), school age (from 6 or 7 years old to 10 years old before adolescence), and adolescence (from 10 to 20 years old) [3]. Newborns have a strong capability for wound healing and are generally treated conservatively unless there are exceptional circumstances; the wound healing characteristics and management approaches of school-age children and adolescents are more similar to those of adults. Therefore, the recommendation of the Consensus applies mainly to early childhood and preschool children aged 1 to 6.

Clinical issues and recommendations

Clinical issue 1: Definition and diagnosis of pediatric deep partial-thickness burn wounds

Recommendations

1. The diagnosis of burn-wound depth is still based on subjective judgments regarding the characteristics of the wound on the 3rd to 5th day after the injury (evidence grade V). The evaluation content includes the color of the wound base (evidence grade V), skin texture (evidence grade V), and any changes in algesia (evidence grade IV).

Recommendation level: highly recommended

Rationale While deep partial-thickness burn injuries affect the epidermal and dermal papillae layers of the skin, some dermal and skin attachments remain. Such injuries generally take 3 weeks or longer to heal [4]. Clinical signs commonly associated with deep partial-thickness burns may include local swelling; the formation of small blisters; a slightly moist, slightly red, or red–white wound base; a tougher texture; a dull pain sensation; and a decrease in temperature [5,6]. The current clinical assessment of burn-wound depths is still based on empirical judgment, i.e. the physician-in-charge makes a subjective judgment based on the clinical characteristics of the wound [7]. Healing time serves as an important criterion for confirming the diagnosis of the burn-wound depth, and patients who complete re-epithelialization within 3 to 4 weeks after the injury are generally considered to have deep partial-thickness burns [5]. It has also been reported that epithelialization is generally completed 21–35 days after injury [8]. In the early postinjury period, there may be a dynamic process of wound deepening [5]; therefore, a dynamic assessment within 72 hours or on the 5th day postinjury is recommended [8].

Advancements in supplementary diagnostic technologies, including laser Doppler imaging [9], thermography, spectroscopy, and magnetic resonance imaging, have facilitated the objective assessment of burn depths. In the future, histopathological examination, objective diagnostic technologies, and artificial intelligence will enable clinicians to make objective and accurate judgments of burn depths, thereby assisting in surgical decision-making [10].

Clinical issue 2: Surgical treatments of pediatric deep partial-thickness burn wounds

There is a positive correlation between the degree of scar hypertrophy and the duration of wound healing. Studies have consistently reported a significantly higher incidence of hypertrophic scarring in wounds that take more than 21 days to heal compared to wounds that heal within 21 days [11,12]. This has led to the suggestion that surgical treatment should be administered when the estimated time for wound healing exceeds three weeks. However, a study comparing the occurrence of scars in children treated surgically and nonsurgically [12] revealed the following findings: the incidence of hypertrophic scarring was 56.5% in the conservative group and up to 80% in the surgical group for patients with wound healing times between 22 and 30 days; for those with wound healing times longer than 30 days, the incidence of hypertrophic scarring was 85.7% in the conservative group and 86.7% in the surgical group [12]. This study suggests that for deep partial-thickness burn wounds that may take 20 to 30 days to heal, surgical intervention does not demonstrate substantial advantages. In recent years, advancements in wound management technology and comprehensive scar rehabilitation methods, including modern wound dressings with multiple functions, have significantly reduced the healing time of deep burn wounds [13–16]. Comprehensive scar treatment that combines various therapeutic approaches has

greatly improved the prognosis of pediatric deep burns. As a result, there has been a growing trend toward more stringent criteria for surgical intervention in cases of pediatric deep partial-thickness burns.

According to case reports in China, early surgical intervention (i.e. within 72 hours) using tangential excision and eschar grinding to remove necrotic tissue, followed by the application of biological dressings, has been shown to expedite wound healing and reduce the occurrence of complications [17]. These findings demonstrate a trend toward active early debridement and effective wound coverage along with conservative skin grafting for pediatric deep partial-thickness burn wounds.

Early debridement and surgical debridement

Recommendations

2. For deep partial-thickness burn pediatric patients with burn area $\leq 15\%$ TBSA with stable circulation, debridement can be performed within 24 hours after the injury, and the wounds should be covered with moisturizing dressings or biosynthetic dressings (evidence grade IIc). For patients with burn area $\leq 15\%$ TBSA with risk of shock, the debridement should be postponed until adequate fluid resuscitation and circulatory stability have been achieved (evidence grade V).

Recommendation level: highly recommended

3. For deep partial-thickness burn pediatric patients with burn area $> 15\%$ TBSA, we recommend removing necrotic tissue from the wounds using eschar grinding or tangential excision in thin layers and covering the wound with various moisturizing dressings (evidence grade V). This procedure should be typically operated after shock stage when adequate fluid resuscitation and circulatory stability have been achieved. In burn centers with respiratory and circulatory monitoring and support, the timing of surgery may be appropriately accelerated based on the specific circumstances of the patient (evidence grade V).

Recommendation level: highly recommended

Rationale For pediatric patients with burn area $\leq 15\%$ total body surface area (TBSA) with stable circulation, debridement can typically be performed within 24 hours after the injury. However, for children with burn area $> 15\%$ TBSA with risk of shock, we generally recommend waiting for adequate fluid resuscitation and circulatory stability before surgery. In burn centers equipped with respiratory and circulatory monitoring and support, the timing of surgery may be appropriately accelerated. After debridement, the wounds can be covered with allogeneic or heterogeneous skin, a biological wound protection membrane prepared from porcine visceral membrane, a moisturizing functional wound dressing, or other biological and biosynthetic dressings [7,18].

For patients with deep partial-thickness burns who have not undergone early debridement or who have a considerable

Table 2. A summary of 18 consensus recommendations

Consensus recommendations	Key words	Recommendation level	Key notes
Clinical Issue 1: Definition and diagnosis of pediatric deep partial-thickness burn wounds			
1	Definition and diagnosis	Highly recommended	Subjective + specialist physical examination
Clinical Issue 2: Surgical treatments of pediatric deep partial-thickness burn wounds			
2	Surgical principle	Highly recommended	24 hours, 15% TBSA
3	Surgical option	Highly recommended	15% TBSA, eschar grinding or tangential excision
4	Surgical timing	Recommended	3 to 5 days, one week, two weeks
5	Surgical indication	Highly recommended	3 to 4 weeks
6	Surgical scope	Highly recommended	Surgery on the functional sites
Clinical Issue 3: Nonsurgical treatment of pediatric deep partial-thickness burn wounds			
7	Fresh and clean wound	Recommended	Preservation of epidermis + drainage
8	Soiled/infected/large wounds	Highly recommended	Topical antibacterial
9	Pain management	Highly recommended	Comfort
Clinical Issue 4: Dressing for pediatric deep partial-thickness burn wounds			
10	Frequency of dressing changes	Highly recommended	Combined with the characteristics of wound and dressing
11	Coverings for wounds at special sites	Highly recommended	Face and perineum
12	Selection of coverings for nonsurgical treatment	Highly recommended	Modern wound dressing
Clinical Issue 5: Treatment of infectious pediatric deep partial-thickness burn wounds			
13	Timing of pathogenic examination of wound	Recommended	Wound bacterial culture + drug sensitivity
14	Timing of pathogenic examination of medium to large-area burn wounds	Highly recommended	The first dressing change + regular collection
15	Timing of pathogenic examination of infected wounds	Highly recommended	Signs of infection/3–5 days after anti-inflammatory therapy
16	Frequency of dressing change for infected wounds	Highly recommended	Dynamic evaluation and timely adjustment
17	Wounds with high risk of infection	Highly recommended	Topical antibacterial and dynamic adjustment
Clinical Issue 6: Prevention and treatment of scars from pediatric deep partial-thickness burn wounds			
18	Scar prevention	Highly recommended	Informed, early and comprehensive

amount of remaining necrotic tissue during reassessment 3 to 5 days after initial debridement, surgical approaches such as eschar grinding, tangential excision in thin layers, and hydrosurgery can be utilized to remove necrotic tissue from the wound surface [8] while preserving as much healthy tissue as possible [19]. After debridement, wounds can be covered with moisturizing dressings. The above method enables most wounds to heal within 21 days and significantly reduces the risk of wound infection [7,20]. It can also be combined with negative pressure wound therapy (NPWT) [19] to preserve the maximum amount of wound tissue possible.

The timing and scope of skin grafting surgery

Recommendations

4. Dynamic evaluation of the pediatric deep partial-thickness burn wounds is recommended 3 to 5 days after the injury (evidence grade V). If skin grafting is necessary, we recommend completing necrotic tissue removal within 1 week (evidence grade IIIb) and performing skin grafting within 2 weeks after the injury (evidence grade V).

Recommendation level: recommended

Rationale The wound should be dynamically evaluated 3 to 5 days after the injury. If skin grafting is needed, necrotic tissue removal should be completed within 1 week after the injury, and skin grafting should be performed within 2 weeks postinjury [21]. If the child's general condition is stable and the scope of the wound is relatively small, tangential excision and autologous skin grafting can be performed simultaneously. However, if circumstances do not permit, we recommend initiating conservative treatment and assessing the need for skin grafting based on the progress of the wound. Compared to surgical treatment within 72 hours after the injury, a strategy of conservative treatment within 2 weeks, followed by a decision on whether to perform skin grafting based on wound progress, can significantly reduce the scope of the surgery and intraoperative blood loss as well as shorten the operation time [22,23]. After the first tangential excision, the wound should be covered with allogeneic or heterogeneous skin, animal visceral membranes, and other biological dressings or biosynthetic dressings with good moisturizing properties. Subsequent skin grafting may be performed once or multiple times, depending on the availability of autologous skin sources. If there is an adequate supply of autologous skin, large sheets of medium-thick skin grafts should be used for

exposed or functional areas such as the face, hands, feet, and joints.

Indications and approaches to skin grafting

Recommendations

5. For deep partial-thickness wounds with an estimated healing time of 3–4 weeks, tangential excision should be considered (evidence grade IIb). The subsequent decision to proceed with autologous skin grafting or specific skin grafting techniques should be based on factors such as wound size, location, and presence of remaining epithelial islands (evidence grade V).

Recommendation level: highly recommended

6. Deep partial-thickness burn wounds that are relatively deep in functional sites such as the hand (evidence grade IIc), elbow (evidence grade V), shoulder/knee (evidence grade V) and neck (evidence grade V), where hypertrophic scars formed after healing may substantially affect the functional activity of the site, should be considered for skin grafting (evidence grade V). If tangential excision results in removing all dermis, the use of large pieces of thin or split-thickness skin graft or full-thickness skin graft is recommended, and composite transplantation may also be considered. If there is dermis remaining after tangential excision, razor-thin graft or split-thickness skin grafting can be performed depending on the thickness of remaining dermis on wounds to improve the scar hyperplasia on both the donor and the grafting site (evidence grade V).

Recommendation level: highly recommended

Rationale For deep partial-thickness burn wounds that are relatively deep or that have deepened due to various factors and are estimated to take more than 4 weeks to heal, we recommend treatment with tangential excision and skin grafting.

For deep partial-thickness burn wounds that are relatively deep in functional sites such as the hand, elbow, shoulder, or knee, where the formation of hypertrophic scars after healing could substantially impact functional activity, surgical treatment should be considered. In circumstances where necrotic tissue has been removed in the early stages through tangential excision, which cuts nearly all of the dermis, relatively thick or intermediate-thickness skin grafting is recommended at the same time (the donor site can be covered by split-thickness skin). Composite skin grafting may also be considered. If dermis remains after tangential excision, split-thickness skin grafting can be performed to improve both the donor site and the grafting site. Early skin grafting, combined with early rehabilitation, can promote functional recovery and reduce the disability rate of the joint parts [24]. However, when considering skin grafting surgery for deep partial-thickness burn wounds on the face, caution should be exercised due to the potential for creating a ‘patch-like’ appearance after grafting. Additionally, thick-skinned areas such as the palm,

sole, and back are generally considered unsuitable for surgical treatments.

Large, deep, partial-thickness burns can induce systemic inflammatory response syndrome and lead to functional impairment of systematic tissue and organs. Failing to remove necrotic tissue promptly can lead to invasive wound infection and even burn-wound sepsis, threatening the life of the child. According to a study, a burn area exceeding 60% TBSA is associated with significantly higher mortality rates [25]. Children with deep partial-thickness burns with over 20% TBSA are referred for early surgical treatment and timely removal of necrotic tissue [4,8]. Since children are still in the process of development, whenever possible, the preferred method for removing necrotic tissue is tangential excision to preserve fatty tissue, maintain tissue fullness, and improve long-term prognosis.

The advantages of NPWT include reduction of edema, promotion of granulation growth, reduction of the bacterial load of the wound, acceleration of epithelialization, improvement of skin graft viability, and reduction of scar formation risk [26–30]. It has been reported that NPWT can be directly applied to deep partial-thickness burn wounds [27] or used in conjunction with modern dressings [27,31]. Because of its good braking and fixing effect on skin grafts, NPWT is also often used for skin graft fixation after pediatric grafting surgery, especially in areas that are difficult to wrap, such as the neck, axilla, and hands [32]. In foreign countries, a continuous negative pressure mode of –50 to –75 mmHg has been recommended for children under 2 years of age and –75 to –125 mmHg for children over 2 years old [32]. According to the relevant consensus in China [33], it is recommended that a continuous negative pressure mode be adopted in children to relieve pain, with a suggested range of –75 to –25 mmHg for children younger than 2 and –75 to –50 mmHg for children between 2 and 12 years old. The application of NPWT to large burn wounds carries a risk of fluid loss and requires close observation of drainage.

Compared to conventional tangential excision, hydrodynamic debridement does not show important differences in terms of skin graft viability and scar scores at 6 months after surgery. However, histological evidence suggests that this technology preserves more viable dermal tissue [34]. Hydrodynamic debridement is particularly suitable for sites with limited tissue or uneven surfaces, such as a child’s fingers, toes, face, neck, and perineum [35]. Using hydrodynamic debridement before skin grafting on a granulation wound can decrease the incidence of infection and improve the survival rate of the grafted skin.

Clinical issue 3: Nonsurgical treatment of pediatric deep partial-thickness burn wounds

Recommendations

7. For fresh and clean deep partial-thickness burn wounds, the blister fluid can be drained (evidence grade IIIb) while

preserving the blister skin. The blister skin can be preserved for the first 3 days after the injury (evidence grade V). A longer time could be considered if there have been no signs of subcutaneous infection.

Recommendation level: recommended

8. Contaminated and possibly infected wounds should undergo debridement and removal of blister skin, followed by the application of topical antibacterial medication (evidence grade Ia) or functional wound dressings containing antibacterial components (evidence grade Ia). Dressings should be changed daily or every other day (evidence grade V).

Recommendation level: highly recommended

9. Pain management during wound treatment operations contributes to the comfort and compliance levels of the child (evidence grade IIb). Debridement should be performed under analgesic conditions whenever possible. In cases involving multiple sites or large burn wounds, higher levels of analgesia are necessary (evidence grade V).

Recommendation level: highly recommended

10. For early postinjury wounds with high exudation or a risk of infection, we recommend changing the dressings every 1–2 days (evidence grade IIb). The interval between dressing changes should be adjusted based on the condition of the wound and the type of topical medication or dressing applied.

Recommendation level: highly recommended

Rationale The nonsurgical treatment principles for pediatric deep partial-thickness burn wounds focus on preventing infection, protecting the remaining epithelial tissue, and creating an optimal healing environment for wound re-epithelialization. Advancements in modern wound dressings and comprehensive scar rehabilitation have significantly improved the prognosis of pediatric deep burn wounds [36]. Foreign studies have shown that children with moderately deep burns who undergo conservative treatments within 72 hours after the injury generally have a better overall prognosis than those who undergo surgical treatment within the same timeframe [22]. In a study comparing the effects on pediatric deep partial-thickness burn wounds among early tangential excision with grafting, physical debridement combined with modern wound dressings, and conservative treatment with modern wound dressings alone, no significant advantages were found for early surgical tangential excision and grafting in terms of healing time, bacterial detection rate, or reduction of hypertrophic scar formation [8].

Nonsurgical treatment is feasible for all pediatric deep partial-thickness burn patients who do not meet the indications for surgical treatment and for those who refuse surgical treatment. Nonsurgical treatment can also be optional for children with large wound areas and an uneven depth distribution as well as for children whose systematic conditions are unsuitable for surgery. Topical antibacterial medication or modern wound dressings can be applied to the wound

until the relatively shallow wounds have healed, followed by surgical treatments for deep wounds.

For fresh and clean deep partial-thickness burn wounds, the blister fluid can be drained while preserving the blister skin when changing dressings within 1–3 days after the injury. The blister skin can normally be preserved for 3–5 days postinjury; if the wound is clean without subcutaneous infection, a longer time may be considered. When the epidermis is peeling off and the wound base is exposed, we recommend using a functional wound dressing or topical antibiotic ointment gauze to cover the wound. The interval between dressing changes typically ranges from 2 to 7 days and depends on factors such as wound infection, the amount of exudate, and the effectiveness of the dressing. It is important to closely monitor children's wounds and general condition during dressing changes, and prompt adjustments to the treatment plan should be made if there are any signs of wound infection.

In deep partial-thickness burn wounds, infection can destroy skin attachments and delay epithelialization [37]. Except for small and clean wounds, we recommend using topical antibacterial medication or antibacterial dressings for deep partial-thickness burn wounds. In view of their potential cytotoxicity [38,39] and the risk of adverse reactions (including wound pain), the use of topical antibacterial medication in pediatric burn wounds is gradually being replaced by functional wound dressings with antibacterial components. However, considering the differences in economic conditions among regions, the Consensus does not indicate any preferences between functional wound dressings and pharmaceutical preparations.

Pain can induce stress responses in children and delay epithelialization in severe cases [4,40]. The use of analgesia during dressing changes for pediatric burn wounds has received increasing attention, and expert consensus on this topic has been published in China [41]. Debridement of large wounds should be performed under analgesic conditions whenever possible. For multiple sites and large burn wounds, the level of analgesia needs to be upgraded, and if necessary, debridement can be performed under general anesthesia.

Clinical issue 4: Dressing for pediatric deep partial-thickness burn wounds

Recommendations

11. For areas that are difficult to wrap, such as the face, neck and perineum, if the wound is clean, functional dressings or biological dressings with good adherence properties are recommended (evidence grade IIb). If there is a possibility of wound infection, topical antibacterial medications (evidence grade V) can be used for semiexposure therapy to retain moisture and prevent infection.

Recommendation level: highly recommended

12. In addition to topical antibacterial medications, various types of functional dressings with self-soluble debridement (evidence grade IIb), exudate absorption properties,

and antibacterial effects can also be used in the nonsurgical treatment of pediatric deep partial-thickness wounds.

Recommendation level: highly recommended

Rationale The ideal wound dressing should isolate pathogens and create a favorable wound environment for healing, exhibit a self-soluble debridement effect, maintain a moisturizing and breathable environment with good adsorption capacity while preventing skin maceration, have an antibacterial effect and adherence properties, avoid causing damage to the wound and the surrounding area, and be safe and convenient for use without the need for frequent replacements [1,42].

Suitable dressings for pediatric deep partial-thickness burn wounds after eschar grinding or tangential excision mainly include various types of biological dressings, including allogeneic or heterogeneous skin, amniotic membrane, chitin, and biological wound protection membrane [43]. Following eschar grinding or tangential excision, some wounds can heal spontaneously under the protection of such biological dressings. However, some types of biological dressings with poor water retention properties may cause wound dehydration and dryness. To address this issue, we recommend covering the wound with petroleum jelly gauze.

In recent years, modern wound dressings such as hydrocolloids, hydrogels, alginate dressings, foam dressings [35,44] and hydrophilic fiber dressings [45–48] have become increasingly widely used in clinical applications. These dressings possess good chemical and biological properties and partly resemble the barrier function of the skin, creating a physicochemical environment conducive to wound healing in terms of temperature, humidity, and pH value [49]. The self-soluble debridement, promotion of granulation growth, and re-epithelialization properties exhibited by these dressings have enabled a substantial portion of deep partial-thickness burn wounds, which previously needed surgical treatment, to heal effectively with nonsurgical approaches.

The healing pattern of deep partial-thickness wounds consists of necrotic tissue dissolution and shedding, granulation tissue formation, and re-epithelialization. Hydrogel dressings, hydrocolloid dressings, alginate dressings, hydrophilic fibers, and dressings of foam with special coatings such as soft silicone and nylon or carboxymethyl fiber composite wound dressings contain certain self-soluble debridement properties as well as analgesic and healing-promoting effects [46–48,50,51]. Such dressings are particularly suitable for use in the early postinjury stage. As the necrotic tissues on the wound shed off and the re-epithelialization process accelerates, the healing environment needs to be adjusted from one that is relatively moist, hypoxic, and conducive to necrotic tissue shedding and granulation tissue formation to one that is well drained, relatively dry, normoxic, and suitable for re-epithelialization. Foam dressings containing silver and silver dressings with a soft silicone coating are more appropriate for this stage. We also recommend switching to relatively

narrow-spectrum topical antibacterial medications that cause less disruption to wound healing, such as mupirocin, fusidic acid, and compound polymyxin ointment, depending on the bacterial strain present on the wounds.

Clinical issue 5: Treatment of infectious pediatric deep partial-thickness burn wounds

Recommendations

13. The routine pathogenic diagnosis of wounds is not in high priority in pediatric deep partial-thickness burn wounds with burn area $\leq 15\%$ TBSA (evidence grade IV). A wound pathogenic examination and drug sensitivity test should be performed when obvious symptoms of infection are observed to provide evidence for the selection of topical or systematic antibiotics.

Recommendation level: highly recommended

14. For pediatric deep partial-thickness burn wounds with burn area $> 15\%$ TBSA (evidence grade IV), we generally recommend collecting wound secretions for bacterial or fungal cultures as well as drug sensitivity testing during the first dressing change after admission and at regular intervals thereafter to provide evidence for selecting appropriate antibiotics in case of invasive infection at the burn-wound site (evidence grade V).

Recommendation level: highly recommended

15. Following the appearance of clear signs of infection at the deep second-degree burn-wound site (evidence grade V) and after 3–5 days of antimicrobial treatment (evidence grade IV), we recommend performing another pathogen examination on the wound secretion. This re-evaluation would provide evidence for adjusting the treatment approach accordingly.

Recommendation level: highly recommended

16. The frequency of dressing changes for infected wounds should be determined based on the bacterial load, the inflammatory infiltration of the wound, the exudate amount, and the duration of the drug action. For infected wounds in general, dressings can be changed once a day, and this frequency can be increased if there is severe infection (evidence grade V). The infection status of the wound and the progress of healing should be evaluated during each dressing change, and the treatment used should be adjusted accordingly (evidence grade V).

Recommendation level: highly recommended

17. For pediatric deep partial-thickness burn wounds with a high risk of infection, topical antibacterial medications or antibacterial dressings are recommended (evidence grade IIc). As the cytotoxicity of topical antibacterial medications dressings can delay wound healing, the type, dosage, and duration of application of topical antibacterial medications should be based on comprehensive consideration of managing wound infection while minimizing the risk of delayed healing.

Recommendation level: highly recommended

Rationale Wound infection can destroy residual skin attachments, delay healing, and increase the degree of scar hypertrophy. In the case of burn-wound sepsis, systematic organ function can be affected. Burn wounds are generally contaminated within 48 hours after the injury [52]. Microflora from the normal skin and gastrointestinal tract, as well as pathogens from the hospital environment, subsequently begin to colonize the wounds. *Staphylococcus* and *Streptococci pyogenes* are the most common pathogens in burn wounds within the first week. As time progresses, gram-negative bacteria such as *Pseudomonas aeruginosa*, *Enterobacterium*, and *Acinetobacter* gradually dominate the wound flora, among which there is no lack of multidrug-resistant bacteria. The use of broad-spectrum antibiotics can also lead to fungal colonization and even infection [2].

Signs of wound infection include increased exudation; purulent or bloody discharge or dryness without pus; odor; changes in the wound color to dark red or scarlet red with bleeding spots scattered on the wound base; substantial deepening or cessation of growth of the wound; inflammation infiltration; and cellulitis at the edge of the wound. In the case of systemic infection, clinical manifestations of systematic infection and corresponding changes in laboratory tests are also observed.

In cases of invasive wound infection or systematic infection, bacteriological examination of the wound and systematic application of sensitive antibacterial medications should be performed in a timely manner. The frequency of changing dressings should be increased topically on the wound as well. Topical antibacterial medications are preferred for their high topical drug concentration and lack of adverse reactions, unlike systematic antibiotics [42]. Meanwhile, topical antibacterial medication application could inhibit the growth of wound bacteria without interfering with the healing process and significant adverse reactions [42]. Silver sulfadiazine [53], mafenide, silver zinc emulsion, compound polymyxin sulfate ointment [54], mupirocin, recombinant lysostaphin, fusidic acid ointment, and iodine solution [55] are all examples of clinically available topical antimicrobial agents (formulations).

Many modern functional wound dressings have built-in antibacterial properties, which are often achieved by including silver ions or nanoparticles. Regardless of the type of dressing applied, the key considerations for infected wounds should be antibacterial activity and drainage [56]. Functional dressings have a demonstrated ability to promote wound healing compared to silver sulfadiazine. They offer added advantages such as comfort and ease of handling, and they are increasingly being used in clinical practice [57]. A variety of dressings containing silver ions are currently available for clinical use [46–47,56]. The selection of dressings should account for factors such as the bacterial load of the wound, wound infection, and the antibacterial and drainage effects of the dressing.

Clinical issue 6: Prevention and treatment of scars from pediatric deep partial-thickness burn wounds

Recommendations

18. Pediatric deep partial-thickness burn wounds are usually accompanied by the formation of varying degrees of hypertrophic scarring after healing (evidence grade IIIa), and the patients' families need to be informed as early as possible to obtain their understanding and cooperation. Comprehensive antiscarring treatments such as application of silicone-based products (evidence grade IIIb), pressure therapy (evidence grade IIa), and phototherapy (evidence grade IIb) should be commenced early on and include regular follow-up visits.

Recommendation level: highly recommended

Rationale Scars from pediatric deep partial-thickness burn wounds can be treated with reference to the *Expert Consensus on Clinical Scar Prevention and Treatment in China* [58] and the *Consensus on Early Treatment of Scars* (2020 Edition) [59].

Scar treatment in such cases should begin once the wound has completed re-epithelialization. Depending on the risk of hypertrophic scarring, various approaches may be adopted, including topical medications, pressure therapy, and phototherapy. If scar growth cannot be controlled, intralesional glucocorticoid injections may also be adopted, in addition to topical medications combined with compression therapy. Treatment of hypertrophic scars in children should not include radiation therapy, the antitumor chemotherapy drug 5-fluorouracil, or crotoxin injections. Furthermore, daily care measures for scars, such as the application of sunscreens and avoidance of spicy foods, should be observed.

Discussion

In addition to the strategies introduced in the Consensus, growth factors, NPWT and hydrodynamic debridement are all applied in treating pediatric deep partial-thickness burn wounds. Growth factors serve various functions, including regulating cell proliferation, migration, and differentiation during wound healing. In China, they are widely used in pediatric burn wounds to accelerate healing and improve prognosis. Fibroblast growth factor (FGF) can promote cell proliferation and angiogenesis. When applied to pediatric deep partial-thickness wounds, b-FGF shortens the healing time and reduces the proportion of hypertrophic scars [60]. Epidermal growth factor can stimulate the growth and regeneration of epidermal cells, accelerating re-epithelialization. Furthermore, recombinant human epidermal growth factor can promote healing of pediatric deep partial-thickness wounds, reduce wound exudate, and minimize scar formation [61,62]. Much research has reported the positive effects of using topical growth factors in treating deep second-degree burn wounds in children. Given the current lack of safety and

efficacy studies on topical growth factor products for children younger than 18, this consensus does not recommend the use of growth factors for treating deep second-degree burn wounds in children. We hope that, in the future, there will be more high-quality RCTs confirming the effectiveness and safety of using topical growth factors for this purpose.

Although NPWT and hydrodynamic debridement showed various advantages, there has been a lack of systematic studies on their application in pediatric deep partial-thickness burn wounds. In addition, both NPWT and hydrodynamic debridement can be costly, and NPWT carries the risk of bleeding and fluid loss. Therefore, the current consensus does not offer opinions on the application of NPWT and hydrodynamic debridement.

With the promising development in functional wound dressings with both diagnostic and therapeutic functions based on the specific diagnosis of burn depth [63] and the widespread application of stem cell technology, we expect that the strategy of deep partial-thickness burn-wound treatment will prosper in the future.

Conclusions

According to the existing evidence-based medical evidence and the clinical practice of experts in burn and related fields at home and abroad, this consensus was formulated through the discussion of multidisciplinary experts on several issues related to the clinical diagnosis and treatment of thermally induced deep partial-thickness burn wounds in children aged 1–6 years. Thereby, the consensus provides an academic basis and guiding opinions for the management of deep partial-thickness burn wounds in children.

Publications searching group

Shanghai Jiao Tong University School of Medicine Jia-ao Yu, Shan Zhong, Hsin-Ying Liu, Xuelian Chen, Jiaqiang Wang.

Evidence grading group

Ruijin Hospital Affiliated to Shanghai Jiao Tong University School of Medicine Bo Yuan, Liang Qiao, Jizhuang Wang, Jie Zhang, Dan Liu, Min Gao, Gai Zhang.

Writing group

Ruijin Hospital Affiliated to Shanghai Jiao Tong University School of Medicine Chenghao Lu, Yan Liu, Bo Yuan.

Availability of data

The present Consensus do not include any datasets.

Funding

Shanghai Directed Projects of Biopharmaceutical Field (22DX1900600); Shanghai Research Center for Burn and Wound Repair

(2023ZZ02013); Shanghai Municipal Key Clinical Specialty of China (shslczdzk02302).

Registration of consensus and guidelines

International Practice Guideline Registry Platform, PREPARE-2023CN142.

Conflicts of interest

The authors have disclosed that they do not have any potential conflicts of interest

References

1. ISBI Practice Guidelines Committee; Steering Subcommittee; Advisory Subcommittee. ISBI practice guidelines for burn care. *Burns*. 2016;42:953–1021.
2. ISBI Practice Guidelines Committee; Advisory Subcommittee; Steering Subcommittee. ISBI practice guidelines for burn care, part 2. *Burns*. 2018;44:1617–706.
3. Wang P. *Pediatrics*, The 8th edn. People's Medical Publishing House, 2013.
4. Herndon DN. *Treatment of Burns*. China Science and Technology Press, 2020.
5. Yang Z. *Treatment Burns*. Shanghai Scientific & Technical Publishers, 1985.
6. Li A. *Li Ao Burn Science*. Shanghai Scientific & Technical Publishers, 2001.
7. Gravante G, Delogu D, Giordan N, Morano G, Montone A, Esposito G. The use of Hyalomatrix PA in the treatment of deep partial-thickness burns. *J Burn Care Res*. 2007;28:269–74.
8. Kaźmierski M, Mańkowski P, Jankowski A, Harasymczuk J. Comparison of the results of operative and conservative treatment of deep dermal partial-thickness scalds in children. *Eur J Pediatr Surg*. 2007;17:354–61.
9. Shin JY, Yi HS. Diagnostic accuracy of laser Doppler imaging in burn depth assessment: systematic review and meta-analysis. *Burns*. 2016;42:1369–76.
10. Cirillo MD, Mirdell R, Sjöberg F, Pham TD. Improving burn depth assessment for pediatric scalds by AI based on semantic segmentation of polarized light photography images. *Burns*. 2021;47:1586–93.
11. Cubison TC, Pape SA, Parkhouse N. Evidence for the link between healing time and the development of hypertrophic scars (HTS) in paediatric burns due to scald injury. *Burns*. 2006;32:992–9.
12. Lonie S, Baker P, Teixeira RP. Healing time and incidence of hypertrophic scarring in paediatric scalds. *Burns*. 2017;43:509–13.
13. Resch A, Staud C, Radtke C. Nanocellulose-based wound dressing for conservative wound management in children with second-degree burns. *Int Wound J*. 2021;18:478–86.
14. Vloemans AF, Hermans MH, van der Wal MB, Liebrechts J, Middelkoop E. Optimal treatment of partial thickness burns in children: a systematic review. *Burns*. 2014;40:177–90.
15. Lau CT, Wong KK, Tam P. Silver containing hydrofiber dressing promotes wound healing in paediatric patients with partial thickness burns. *Pediatr Surg Int*. 2016;32:577–81.

16. Saba SC, Tsai R, Glat P. Clinical evaluation comparing the efficacy of aquacel ag hydrofiber dressing versus petrolatum gauze with antibiotic ointment in partial-thickness burns in a pediatric burn center. *J Burn Care Res.* 2009;30:380–5.
17. Yang XF, Cai XF, Guan XT. Summary of early surgical treatment of pediatric deep partial-thickness burns. *Chinese Pediatrics of Integrated Traditional and Western Medicine.* 2014;3:248–9.
18. Chi Y, Yin H, Chen X, Hu Q, Liu W, Feng L, et al. Effect of precise partial scab removal on the repair of deep partial-thickness burn wounds in children: a retrospective study. *Transl Pediatr.* 2021;10:3014–22.
19. Chinese Burn Association. National expert consensus on the clinical application of eschar dermabrasion in burn wounds (2021 version). *Zhonghua Shao Shang Za Zhi.* 2021;37:501–7.
20. Huang YC, Zhu XM, Liu XM, Qing GP. Observation of the application of heterogeneous decellularized dermal matrix dressing in pediatric burns. *Shaanxi Yi Xue Za Zhi.* 2016;45:1154–5.
21. Desai MH, Rutan RL, Herndon DN. Conservative treatment of scald burns is superior to early excision. *J Burn Care Rehabil.* 1991;12:482–4.
22. Puchala J, Spodaryk M, Jarosz J. *Oparzenia u dzieci: od urazu do wyleczenia: Wydawnictwo UJ,* 1998.
23. Capek KD, Culnan DM, Desai MH, Herndon DN. Fifty years of burn care at Shriners Hospitals for children. *Galveston Ann Plast Surg.* 2018;80:S90–4.
24. QL XU. Effect of treating pediatric special site burns on late function with a holistic concept. In: *Proceedings of the 11th National Symposium on Burn Injury Treatment.* Harbin, 2014, 17.
25. Kraft R, Herndon DN, Al-Mousawi AM, Williams FN, Finnerty CC, Jeschke MG. Burn size and survival probability in paediatric patients in modern burn care: a prospective observational cohort study. *Lancet.* 2012;379:1013–21.
26. Li TR, Li WT, Tuo XY, Yang LL, Xiu YP, Qian XY, et al. Application of vacuum sealing drainage on superficial degree II burn and scald wound: a clinical study in pediatrics. *Clin J Med Offic.* 2016;1:23–5.
27. Koehler S, Jinbo A, Johnson S, Puapong D, de Los RC, Woo R. Negative pressure dressing assisted healing in pediatric burn patients. *J Pediatr Surg.* 2014;49:1142–5.
28. Ren Y, Chang P, Sheridan RL. Negative wound pressure therapy is safe and useful in pediatric burn patients. *Int J Burns Trauma.* 2017;7:12–6.
29. de Jesus LE, Martins AB, Oliveira PB, Gomes F, Leve T, Dekermacher S. Negative pressure wound therapy in pediatric surgery: how and when to use. *J Pediatr Surg.* 2018;53:585–91.
30. Frear CC, Griffin B, Cuttle L, McPhail SM, Kimble R. Study of negative pressure wound therapy as an adjunct treatment for acute burns in children (SONATA in C): protocol for a randomised controlled trial. *Trials.* 2019;20:130.
31. Frear CC, Zang T, Griffin BR, McPhail SM, Parker TJ, Kimble RM, et al. The modulation of the burn wound environment by negative pressure wound therapy: insights from the proteome. *Wound Repair Regen.* 2021;29:288–97.
32. Pedrazzi NE, Naiken S, La Scala G. Negative pressure wound therapy in Pediatric burn patients: a systematic review. *Adv Wound Care (New Rochelle).* 2021;10:270–80.
33. Chinese Burn Association, Editorial Board of Chinese Journal of burns. National expert consensus on the application of negative pressure closed drainage technology in burn surgery (2017 edition). *Zhonghua Shao Shang Za Zhi.* 2017;33:129–35.
34. Hyland EJ, D'Cruz R, Menon S, Chan Q, Harvey JG, Lawrence T, et al. Prospective, randomised controlled trial comparing Versajet™ hydrosurgery and conventional debridement of partial thickness paediatric burns. *Burns.* 2015;41:700–7.
35. Li MY, Mao YG, Guo GH, Liu DW. Application of a hydro-surgery system in debridement of various types of burn wounds. *Zhonghua Shao Shang Za Zhi.* 2016;32:574–6.
36. Gee Kee E, Kimble RM, Cuttle L, Stockton K. Comparison of three different dressings for partial thickness burns in children: study protocol for a randomised controlled trial. *Trials.* 2013;14:403.
37. Selvarajah D, Bollu BK, Harvey J, Jacques M, Jehangir S, Fuller ES, et al. Acticoat versus biobrane: a retrospective review on the treatment of paediatric mid-dermal torso burns. *Int J Burns Trauma.* 2019;9:82–7.
38. Cuttle L, Naidu S, Mill J, Hoskins W, Das K, Kimble RM. A retrospective cohort study of Acticoat versus Silvazine in a paediatric population. *Burns.* 2007;33:701–7.
39. Fraser JF, Cuttle L, Kempf M, Kimble RM. Cytotoxicity of topical antimicrobial agents used in burn wounds in Australasia. *ANZ J Surg.* 2004;74:139–42.
40. Liu Y, Zhang J. Management of pediatric deep partial-thickness burn wounds. *Zhonghua Shao Shang Za Zhi.* 2021;37:797–800.
41. Committee on Burn Injury and Tissue Repair of Association of Medical Exchanges Across the Taiwan Straits. Expert consensus on the application of nitrous oxide and oxygen mixed inhalation for sedation and analgesia technology in burn surgery (2021 version). *Zhonghua Shao Shang Za Zhi.* 2021;37:201–6.
42. Davies MR, Rode H, Cywes S, van der Riet RL. Burn wound management. *Prog Pediatr Surg.* 1981;14:33–61.
43. Guo Y, Cai LL, Yu JJ, Lyu GZ. Clinical observation of aseptic biological wound protection membrane in the treatment of pediatric deep partial-thickness burn wounds. *Chinese Journal of Injury Repair and Wound Healing (Electronic Edition).* 2013;8:56–7.
44. Gee Kee EL, Kimble RM, Cuttle L, Khan A, Stockton KA. Randomized controlled trial of three burns dressings for partial thickness burns in children. *Burns.* 2015;41:946–55.
45. Bowler PG, Jones SA, Walker M, Parsons D. Microbicidal properties of a silver-containing hydrofiber dressing against a variety of burn wound pathogens. *J Burn Care Rehabil.* 2004;25:192–6.
46. Wu JJ, Zhang F, Liu J, Yao HJ, Wang Y. Effect of silver-containing hydrofiber dressing on burn wound healing: a meta-analysis and systematic review. *J Cosmet Dermatol.* 2023;22:1685–91.
47. Wang J, Yang B, Zhang XH, Liu SH, Wu W. The effectiveness of silver-containing hydrofiber dressing compared with topical silver sulfadiazine cream in pediatric patients with deep partial-thickness burns: a retrospective review. *Wound Manag Prev.* 2022;68:29–36.
48. Gao Y, Li JH, Guo ZQ, Zhang XH. Application of hydrogel dressing Aquacel-ag in the treatment of partial thickness burns of the head and face in children. *Chinese Journal of Aesthetic and Plastic Surgery.* 2017;28:485–7.
49. Xu W, Liu Y, Yue J. *Repair of burn wounds.* Hubei Science & Technology Press, 2013.
50. Song DH, Li Y, Liu JS, Hao QY, Zhang XZ, Yu Y. Observation on the effect of silver ion alginate dressing on deep II degree burn wounds on limbs of children. *Infect Inflamm Rep.* 2016;17:199–202.

51. Chen ZL, Wu GS, Zhu SH, Xia ZF. Observation of alginate dressing and polyurethane foam dressing in the treatment of wound in the skin donor site on the head of patients with large burns. *Zhonghua Shao Shang Za Zhi*. 2015;31:135-7.
52. Erol S, Altoparlak U, Akcay MN, Celebi F, Parlak M. Changes of microbial flora and wound colonization in burned patients. *Burns*. 2004;30:357-61.
53. Klasen HJ. A historical review of the use of silver in the treatment of burns.II. Renewed interest for silver. *Burns*. 2000;26:131-8.
54. Lu LC, Chang FY, Lv GZ, Lan SH. Effectiveness and safety of compound Polymyxin B ointment in treatment of burn wounds: a meta-analysis. *J Burn Care Res*. 2022;43:453-61.
55. Malone M, Johani K, Jensen SO, Gosbell IB, Dickson HG, McLennan S, *et al*. Effect of cadexomer iodine on the microbial load and diversity of chronic non-healing diabetic foot ulcers complicated by biofilm in vivo. *J Antimicrob Chemother*. 2017;72:2093-101.
56. Jeschke MG, van Baar ME, Choudhry MA, Chung KK, Gibran NS, Logsetty S. Burn injury. *Nat Rev Dis Primers*. 2020;6:11.
57. Heyneman A, Hoeksema H, Vandekerckhove D, Pirayesh A, Monstrey S. The role of silver sulphadiazine in the conservative treatment of partial thickness burn wounds: a systematic review. *Burns*. 2016;42:1377-86.
58. Development Group of Chineses Expert Consensus on Clinical Prevention and Treatment of Scar. Chinese expert consensus report on clinical prevention and treatment of scar. *Chinese Journal of Injury Repair and Wound Healing (Electronic Edition)*. 2017;12:401-6.
59. Chinese Association of Plastics and Aesthetics Scar Medicine Branch. National expert consensus on early management of scars (2020 version). *Zhonghua Shao Shang Za Zhi*. 2021;37:113-25.
60. Akita S, Akino K, Imaizumi T, Tanaka K, Anraku K, Yano H, *et al*. The quality of pediatric burn scars is improved by early administration of basic fibroblast growth factor. *J Burn Care Res*. 2006;27:333-8.
61. Liang ZQ, Li HM, Meng CY. Repair of second degree facial burns in children using recombinant human epidermal growth factor. *Journal of Clinical Rehabilitative Tissue Engineering Research*. 2007;11:1974-5.
62. Zheng ZZ, Liu JF, Xie WG, Wu RZ, Zhou HP, Wan SY. Application of recombinant human epidermal growth factor in the treatment of children with II degree burn. *Journal of Huazhong University of Science and Technology*. 2003;32:667-8.
63. Ninan N, Forget A, Shastri VP, Voelcker NH, Blencowe A. Antibacterial and anti-inflammatory pH-responsive tannic acid-Carboxylated agarose composite hydrogels for wound healing. *ACS Appl Mater Interfaces*. 2016;8:28511-21.

Appendix

GOVERNANCE OF National Expert Consensus on the Management of Pediatric Deep Partial-Thickness Burn Wounds (2023 Edition).

Methodology consultant: Ruijin Hospital Affiliated to Shanghai Jiao Tong University School of Medicine Jian Li.

Consensus cochairs: Affiliated Hospital of Jiangnan University Guozhong Lyu, The Southwest Hospital of AMU Gaoxing Luo, Ruijin Hospital Affiliated to Shanghai Jiao Tong University School of Medicine Yan Liu.

Consensus committee group: Fuyang Hospital of Anhui Medical University Qinglian Xu, The University of Queensland Roy Kimble, General Hospital of Northern Theater Command Yang Wang; Hospital of North Sichuan Medical College Guofu Zhou; Children's Hospital of Chongqing Medical University Lin Qiu; Fujian Medical University Union Hospital Zhaohong Chen; Gansu Provincial Hospital Jian Wu; Ganzhou People's Hospital Jiajin Tu; Guangdong Provincial People's Hospital Wen Lai; The First Affiliated Hospital of Guangxi Medical University Dehui Li; Guizhou Provincial Peoples Hospital Deyi Zheng; Second Affiliated Hospital, Guizhou University of Traditional Chinese Medicine Jiamin Wu; The Fifth Hospital of Harbin City Zongyu Li; Handan HanGang Hospital Changhong Lu; Changhai Hospital, Naval Medical University Guangyi Wang, Xiaoyan Hu, Daofeng Ben, Hongtai Tang; Hainan General Hospital Yunchuan Pan; The First Hospital of Hebei Medical University Qingfu Zhang; The First Bethune Hospital of Jilin University Jia-ao Yu; Guangzhou Red Cross Hospital Xiaojian Li; Affiliated Hospital of Jiangnan University Guozhong Lyu, Yugang Zhu; The Fourth Medical Center, Chinese PLA General Hospital Xiangbai Ye, Chuan-an Shen, Tianjun Sun; Xijing Hospital, Fourth Military Medical University Hao Guan, Dahai Hu, Juntao Han; Kunming Children's Hospital Jinfeng Fu; Second Affiliated Hospital of Kunming Medical

University Wenjun Liu; The Southwest Hospital of AMU Gaoxing Luo, Zhiqiang Yuan, Guangping Liang; The First Affiliated Hospital of Nanchang University Hongyan Zhang, Guanghua Guo; The First Affiliated Hospital Of University Of South China Chiyu Jia; The Affiliated Hospital of Nankai University Shihai Feng, Yongjian Zhao; Affiliated Hospital of Nantong University Yi Zhang; Baogang Hospital Ba Te; Ningbo No. 2 Hospital Youfen Fan; General Hospital of Ningxia Medical University Ming Yao; Qinghai University Affiliated Hospital Shengwu Chao; West China Second University Hospital, Sichuan University Hong Yan; West China Hospital of Sichuan University Junjie Chen; Shandong Provincial Hospital Affiliated to Shandong First Medical University Ran Huo; The First Affiliated Hospital of Shandong First Medical University & Shandong Provincial Qianfoshan Hospital Yibin Wang; Central Hospital Affiliated to The First Medical University of Shandong Guodong Song; Shanxi Bethune Hospital Zhi Li; Ruijin Hospital Affiliated to Shanghai Jiao Tong University School of Medicine Dongmei Qu, Liang Qiao, Yan Liu, Qin Zhang, Shuliang Lu, Bo Yuan, Xiong Zhang, Jian Li; Seventh People's Hospital of Shanghai University of Traditional Chinese Medicine Shun Xu; The First Affiliated Hospital of Shihezi University School of Medicine Na Lei; Shenzhen Second People's Hospital Jun Wu, Kunwu Fan; Beijing Children's Hospital Yanni Wang, Hongyan Qi; Beijing Jishuitan Hospital Dongning Yu, Yuming Shen, Fengjun Qin; General Hospital of TISCO Peng Duan; Tianjin First Central Hospital Xiaobing Li; The First Affiliated Hospital of Wannan Medical College Dalun Lyu; The Second Affiliated Hospital of Wenzhou Medical University Wenzhen Zhang; The Third Affiliated Hospital of Wenzhou Medical University Jiong Chen; Wuhan Third Hospital Deyun Wang, Shuhua Liu; Ninth Hospital of Xi'an Houan Xiao; Xinjiang Karamay Central Hospitita Huijun Wang; People's Hospital of Xin jiang Uygur Autonomous Region Xiaolong Liu; The Affiliated Hospital of Xuzhou Medical University

Peisheng Jin; Yichun People's Hospital Xiaojin Yi;
The Second Affiliated Hospital of Zhejiang University
School of Medicine Chunmao Han; The First Affiliated
Hospital of Zhengzhou University Zhengjun Cui;
Zhengzhou First People's Hospital Shemin Tian,
Chengde Xia; Anshan Hospital of First Affiliated

Hospital of China Medical University Hongjun Zhai;
Xiangya Hospital, Central South University Pihong
Zhang, Minghua Zhang; The First Affiliated Hospital
of Sun Yat-sen University Xusheng Liu; Affiliated
Hospital of Zunyi Medical University Dali Wang,
Zairong Wei;